



PRESENTING CLINICAL SIGNS

History: Grade V/VI murmur. Receiving enalapril 2.5 mg BID.

DATE

9/20/22

ECHOCARDIOGRAPHIC FINDINGS

2D, M-mode, and Doppler study.

PERFORMED BY:

Kelly Vazquez

INTERPRETED BY

Keith Blass, DVM,
MS, DACVIM
(Cardiology)

There is mild left atrial dilation. The mitral valve leaflets are mildly thickened and exhibit systolic prolapse. A mild to moderate jet of mitral regurgitation is present. There is mild left ventricular dilation. Left ventricular systolic function is hyperdynamic. The aorta and aortic valve are normal. Right atrial and right ventricular dimensions are normal. The tricuspid valve leaflets are mildly thickened, and a mild jet of tricuspid regurgitation is present. The pulmonary artery and pulmonic valve are normal. No shunting lesions are visualized. No pericardial effusion or cardiac masses are seen.

LA - 31.5 mm
LVIDd - 31.2 mm
LVIDs - 15.3 mm
FS - 51%
RA - 19.2 mm
LVOT - 1.32 m/s
RVOT - 0.74 m/s

PATIENT

Starla Vanvlaandern

SPECIES

Canine

BREED

Shih Tzu

ASSESSMENT/RECOMMENDATIONS

Degenerative mitral and tricuspid valve disease

This examination demonstrates regurgitation of blood across Starla's mitral and tricuspid valves resulting from degenerative valve disease. Starla's tricuspid valve disease is mild, and appears to be well-compensated at this time. Her mitral valve disease is a bit more advanced, as Starla has mild secondary dilation of both her left atrium and left ventricle. As only mild left heart chamber dilation is present, Starla's current risk for the development of clinical signs secondary to her mitral valve disease, such as coughing, exercise intolerance, syncope, and labored breathing, appears to be relatively low, though careful monitoring for these signs is still recommended.

SEX

FS

I recommend starting Starla on pimobendan (2.5 mg am, 1.25 mg pm), as this medication should help to slow the progression of her valvular diseases.

AGE

12 y

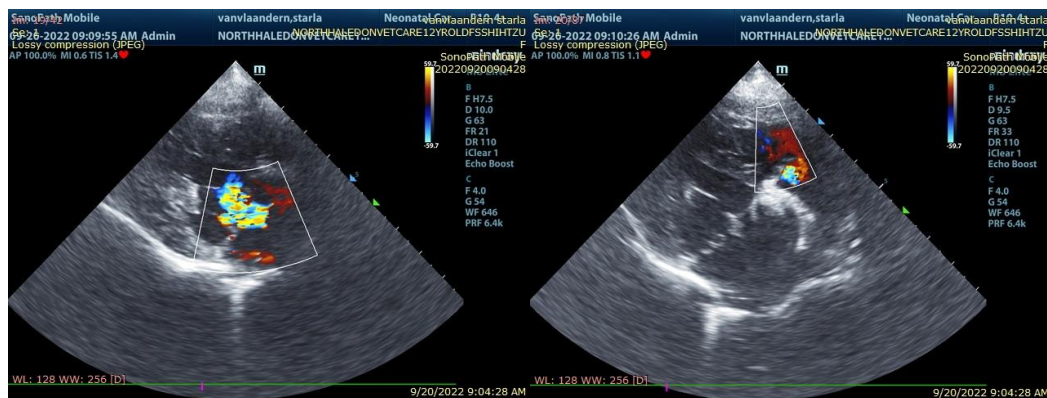
A recheck echocardiogram is recommended in 9 months. Thoracic radiographs are recommended if Starla experiences respiratory clinical signs.

WEIGHT

15.2 lb

HOSPITAL NAME

North Haledon VC



REFERRING VET

Dr. Goldstein



DATE

9/20/22

The information and recommendations provided are based on the images presented by the referring veterinarian. No evaluation can be communicated regarding pathology that was not visible in the image/video clips provided.

PERFORMED BY:

Kelly Vazquez

Thank you for this referral. If the clinical or image interpretation does not parallel your findings or if I can be of any further assistance please contact me.

INTERPRETED BY

Keith Blass, DVM,
MS, DACVIM
(Cardiology)

Keith Blass, DVM, MS, DACVIM (Cardiology)
KeithBlass@gmail.com
631-804-5754

PATIENT

Starla Vanvlaandern

SPECIES

Canine

BREED

Shih Tzu

SEX

FS

AGE

12 y

WEIGHT

15.2 lb

HOSPITAL NAME

North Haledon VC

REFERRING VET

Dr. Goldstein